



**PATIENT**

Kali Challa

**PRESENTING CLINICAL SIGNS**

History: Recheck echo. Diagnosed with UCM in 2015. Grade 3-4/6 heart murmur. ProBNP: 183.

**SPECIES**

Feline

**BREED**

DSH

**SEX**

Female Spayed

**ECHOCARDIOGRAM FINDINGS**

2D, m-mode, color flow and doppler imaging is available. The left ventricular wall is asymmetric, with mild to moderate septal hypertrophy. The PW measures normal. There is a diffusely hyperechoic endocardium consistent with fibrosis and ventricular remodeling. Mild papillary muscle hypertrophy. The right ventricle is subjectively normal in size and morphology. There is no left atrial enlargement present. No right atrial enlargement present. Normal RVOT velocity. There is no obvious systolic anterior motion (SAM) of the mitral valve present; however, the LVOT velocity is not assessed. There is no obvious mitral regurgitation present. No other obvious valvular regurgitation is present. There is no pericardial effusion noted. No pleural effusion appreciated.

**CARDIAC CHART**

**AGE**

13 years

**WEIGHT**

11lbs

**INTERPRETED BY**

Maggie Machen Lamy,  
DVM, DACVIM  
(Cardiology)

FELINE CARDIAC PARAMETERS	BODY WEIGHT (kg)	HR (BPM)	IVSd (cm) (Moise, Pipers)	LVIDd (cm) (Moise, Pipers)	LWVd (cm) (Moise, Pipers)	FS (%)	EF (%)
NORMAL PARAMETER	-----	150-240	0.35-0.55	<2 (mean 1.5)	3.5-0.55	35-67	80-100
PATIENT	5.0		0.69	1.2	0.53		
FELINE CARDIAC PARAMETERS	LA/AO (Boon)	LA/AO HEART BASE (Swe) (Abbott)	LA 2D short axis Base view (cm) (Abbott)		LVOT VEL (m/s)	RVOT VEL (m/s)	E max (m/s)
NORMAL	<1.5	<1.3	<1.2		<1.6	<1.3	<0.9
PATIENT	NM	1.2	1.1			1.2	NM

*\*Note: All measurements based upon multi-modal images and methods. An average value is reported.  
Adapted from June Boon, Veterinary Echocardiography, 1998  
Abbott J & MacLean H JVIM 2006;20: 111-119, Moise et al. Am J Vet Res 47:1476, 1986. Pipers et al. Am J Vet Res 40:882, 1979.*

**IMAGING PERFORMED BY**

L. Mandeville, DVM

**INTERPRETATION OF THE FINDINGS & FURTHER RECOMMENDATIONS**

Hypertrophic cardiomyopathy (HCM) is a rule out diagnosis once a patient is deemed normotensive and euthyroid. Both should be considered in this case. Regardless, the left atrial dimension is normal in this study indicating the risk for clinical issues is low. No cause for the murmur is identified, making it likely physiologic in nature. That being said, an LVOTO is not entirely ruled out in this image set. No additional issues are identified.

Without a prior report, the difference in disease classification may suggest progressive hypertrophy or may simply be a difference in interpretation. No comparison can be made; however, what is seen here appears mild.

No therapy is currently indicated. Atenolol may be recommended in the future should SAM be identified, and the hypertrophy/LA dimension worsen progress. It is important to note however that no medications have been shown to definitively alter long term outcome at this stage regardless.

Monitor at home for any respiratory issues or signs of blood clot events (neurologic change, paralysis, etc.). Anesthetic risk is considered mild, however judicious IV fluid rates are advised to avoid fluid

**INVOICE**

28432

**DATE**

1/18/23

**HOSPITAL NAME**

BetterVet

**REFERRING VET**

Dr. Mandeville



**PATIENT**

Kali Challa

overload. Additionally, drugs that stimulate heart rate should be avoided unless clinically necessary (glycopyrrolate, atropine).

**SPECIES**

Feline

Even with disease identified in this exam, this is not suspected to be a cause of any clinical signs at this time. Serial monitoring of blood pressure is advised in an azotemic cat.

**PLAN**

**BREED**

DSH

A screening blood pressure and thyroid panel is recommended every 6 months. A recheck echocardiogram is recommended in 6 months to assess for progression.

**IMAGES**

**SEX**

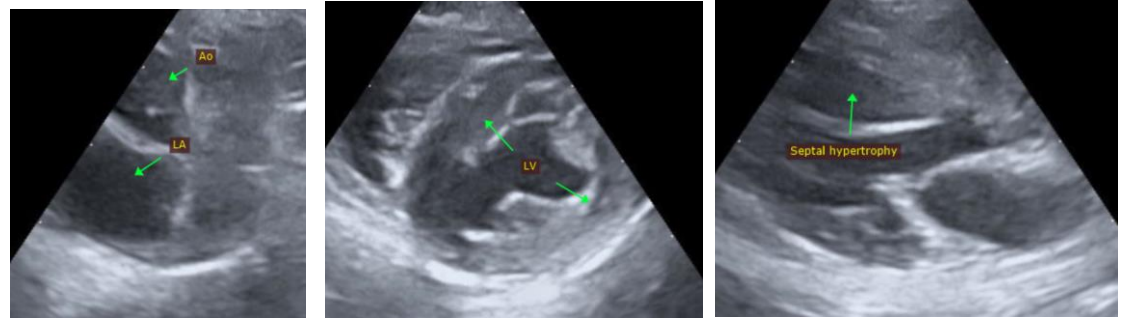
Female Spayed

**AGE**

13 years

**WEIGHT**

11lbs



**INTERPRETED BY**

Maggie Machen Lamy,  
DVM, DACVIM  
(Cardiology)

The information and recommendations provided are based on the images presented by the referring veterinarian. No evaluation can be communicated regarding pathology that was not visible in the image/video clips provided.

Thank you for this referral. This report was generated using transcription software, and minor dictation errors may be present. If the clinical or image interpretation does not parallel your findings or if I can be of any further assistance, please contact me.

**IMAGING PERFORMED BY**

L. Mandeville, DVM

Maggie Machen Lamy, DVM  
Diplomate of the American College of Veterinary Internal Medicine (Cardiology)  
info@sonopath.com

**HOSPITAL NAME**

BetterVet

**REFERRING VET**

Dr. Mandeville

**INVOICE**

28432

**DATE**

1/18/23